

## Redescription of *Besnoitia bennetti* (Protozoa: Apicomplexa) from the donkey (*Equus asinus*)<sup>☆</sup>

J.P. Dubey<sup>a,\*</sup>, C. Sreekumar<sup>a</sup>, T. Donovan<sup>b</sup>, M. Rozmanec<sup>b</sup>, B.M. Rosenthal<sup>a</sup>,  
M.C.B. Vianna<sup>a</sup>, W.P. Davis<sup>c</sup>, J.S. Belden<sup>d</sup>

<sup>a</sup>Animal Parasitic Diseases Laboratory, Agricultural Research Service, United States Department of Agriculture, Animal and Natural Resources Institute, Beltsville Agricultural Research Center, Building 1001, BARC-East, Beltsville, MD 20705-2350, USA

<sup>b</sup>Department of Biomedical Sciences, New York State College of Veterinary Medicine, Cornell University, Ithaca, NY 14853, USA

<sup>c</sup>New Hampshire Veterinary Diagnostic Laboratory, University of New Hampshire, Durham, NH 03824, USA

<sup>d</sup>14800, 46th Lane South, Wellington, FL 33414, USA

Received 23 November 2004; received in revised form 17 January 2005; accepted 19 January 2005

### Abstract

*Besnoitia bennetti* tissue cysts were found in four naturally-infected donkeys (*Equus asinus*) from the USA. Infectivity of its bradyzoites and tachyzoites to animals and cell culture was studied. The bradyzoites were not infectious to out-bred Swiss Webster mice, rabbits or gerbils. When fed tissue cysts, cats did not excrete oocysts. However, the parasite was infectious to interferon-gamma gene knock out mice. The parasite from tissues of two donkeys was grown successfully in bovine monocyte monolayers for the first time. Non-dividing, uninucleate tachyzoites were approximately  $6 \times 1.5 \mu\text{m}$  in size. Longitudinally-cut bradyzoites in tissue sections measured  $8.7 \times 1.9 \mu\text{m}$ . Ultrastructurally, tachyzoites and bradyzoites were similar to those in other *Besnoitia* species, and in particular to parasites described from cattle (*Besnoitia besnoiti*) and reindeer (*Besnoitia tarandi*), in that their bradyzoites lacked enigmatic bodies. Based on comparative analysis of three portions of nuclear ribosomal DNA (the small and large subunits and the first internal transcribed spacer) *B. bennetti* was found to be more closely related to the other congeners described from ungulates. The parasite was formally redescribed and specimens deposited in the US National Parasite Collections.

Published by Elsevier Ltd. on behalf of Australian Society for Parasitology Inc.

**Keywords:** *Besnoitia bennetti*; Donkeys; *Equus asinus*; USA; Mice; Gerbils; Cell culture; Ultrastructure; Sequence analysis; Taxonomy

### 1. Introduction

Species of the coccidian genus *Besnoitia* parasitise cattle, goats, equids, reindeer, caribou, opossums, rabbits, rodents, and lizards (Dubey et al., 2003a). There are several recognised and unrecognised species in the genus but the life cycles of only three (*Besnoitia darlingi*, *Besnoitia wallacei*, and *Besnoitia oryctofelisi*) are known, and morphological differences among the species are poorly defined (Dubey et al., 2003a). Although parasites isolated

from different intermediate host species have traditionally been presumed to represent distinct parasite taxa, it will be difficult to test their actual host specificity until natural definitive hosts are identified.

*Besnoitia bennetti* was first reported by Bennett (1927, 1933) in four horses from Sudan. He believed this parasite was a species of *Sarcocystis* or *Globidium* and that it infected both cattle and horses. Babudieri (1932) transferred this parasite to the genus *Besnoitia*. Schulz and Thorburn (1955) found *Besnoitia* sp. tissue cysts in a horse from South Africa. Pols (1960) listed other unpublished reports of cutaneous besnoitiosis in horses in South Africa and indicated that he could not infect two horses with *Besnoitia besnoiti* of cattle. Bigalke (1970) found *Besnoitia* sp. in donkeys, mules, and horses in South Africa; he was unable to transmit the *Besnoitia* species from equids to cattle or

<sup>☆</sup> Nucleotide sequence data reported in this paper are available in the GenBank, EMBL and DDBJ databases under the accession numbers: AY827838, 827839.

\* Corresponding author. Tel.: +1 301 504 8128; fax: +1 301 504 9222.  
E-mail address: [jdubey@anri.barc.usda.gov](mailto:jdubey@anri.barc.usda.gov) (J.P. Dubey).

from cattle to equids, indicating that equine besnoitiosis may result from a parasite specific to equids. Furthermore, equid *Besnoitia* sp. was not infective to rabbits, hamsters, white mice, or guinea pigs. van Heerden et al. (1993) provided the first ultrastructural description of *B. bennetti* from a horse from South Africa. Lane et al. (1986) reported *B. bennetti*-like tissue cysts associated with laryngeal papillomatosis in a horse imported to England from Argentina. However, the photomicrographs lack details that permit unambiguous diagnosis.

The only reports of equine besnoitiosis out side of Africa are from the USA. Terrell and Stookey (1973) found *Besnoitia* in two of 15 Mexican burrows in a closed experimental herd maintained at the US Army Research Institute, Frederick, Maryland. Davis et al. (1997) found *Besnoitia* sp. in one of eight donkeys on a farm in Montana, USA. Recently clinical besnoitiosis was reported in 14 of 38 miniature donkeys from a herd in Michigan, USA (Elsheikha et al., 2005). To our knowledge, besnoitiosis in horses has not been reported in the USA.

The life cycle of *B. bennetti* is not yet completely known. Only the tissue cyst and bradyzoite stages are known, and

their structures are not fully described. Thus, little basis exists to evaluate whether the same etiological agent establishes infection, and induces disease, in horses and donkeys and possibly in other hosts. Here, we report the successful isolation of *B. bennetti* in culture and in immunodeficient mice, describe the structure of its bradyzoites and tachyzoites, and define portions of its ribosomal DNA to aid its diagnosis and comparison to related coccidia. Specimens are also deposited in museum collections to aid future comparison.

## 2. Materials and methods

### 2.1. Naturally-infected donkeys

#### 2.1.1. Donkey no. 1

A two year old female (Fig. 1E) and her sibling were purchased when seven months old by the present owner from a commercial breeder in Texas. This donkey developed severe pruritus and loss of hair at about 18 months of age, whereas its sibling and two other donkeys (nos. 2–4),

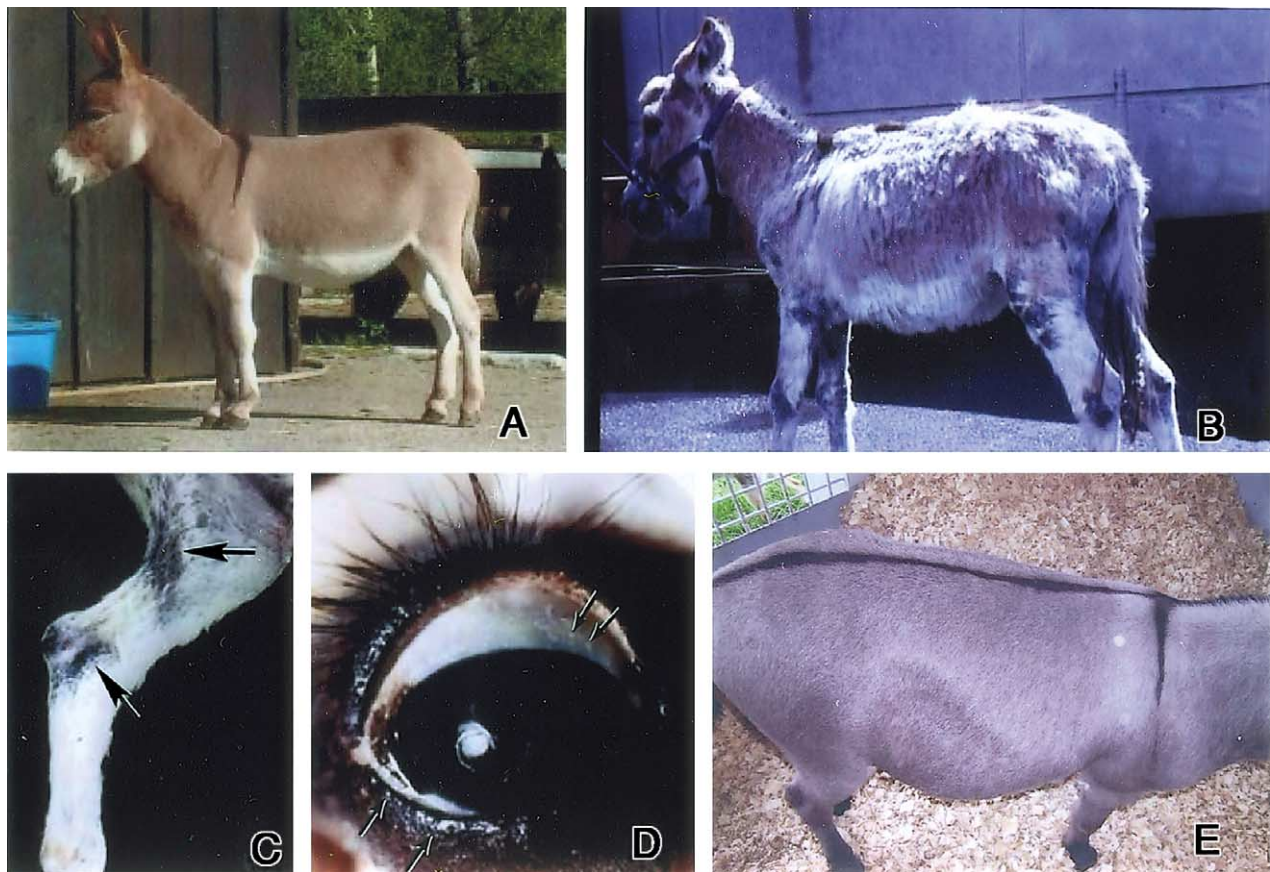


Fig. 1. Lesions and *Besnoitia bennetti* tissue cysts in donkey no. 5. (A) Before onset of clinical signs at approximately one year of age. (B) Before euthanasia, eight months after onset of clinical signs. Note marked cachexia, poor hair coat, and skin lesions (alopecia, hypotrichosis, hyper pigmentation, thickening and crusting) over lateral neck, shoulders, carpi, stifle, hock, periocular region, around ears and muzzle. (C) Lateral aspect of hind limb. Note alopecia and hypotrichosis, with thickened, irregular crusty hyper pigmented skin over caudal aspect of stifle and lateral hock (arrows). (D) Multifocal white pinpoint granular structures (*Besnoitia* tissue cysts) within the sclera and conjunctiva (arrows) of the eye. (E) Lateral view of donkey no. 1 after treatment with SMZ and TM. Note improvement in hair coat.

and seven horses on the same premises remained clinically normal. Haematologic evaluation revealed anaemia (haemoglobin 9.8 d/L, red blood cells  $5 \times 10^6/\text{cm}^3$  haematocrit 28.4%), elevated creatinine phosphokinase (382 U/L), elevated alkaline phosphatase (259 U/L). Cutaneous biopsy revealed granulomatous dermatitis with intralesional *Besnoitia* sp. tissue cysts. Another biopsy was obtained a few weeks later to attempt isolate the parasite in culture. The donkey was treated with sulfamethaxazole (SMZ, 800 mg) and trimethoprim (TM, 160 mg) tablets (five tablets daily) for seven months. Following two months of therapy, folic acid (10 mg) was added to the treatment regime to combat thrombocytopenia, usually associated with sulfonamide treatment. All lesions clinically resolved except a solitary lesion on the bridge of the nose, which was biopsied seven months after the initiation of treatment. Donkey nos. 2–4 were also treated with SMZ and TM for two months although they were clinically normal. Blood samples were obtained from all four donkeys at the time of the last biopsy and a week later from the seven horses.

#### 2.1.2. Donkey no. 5

This miniature 21 month old female donkey (Fig. 1A and B) was born in Vermont and shipped to Massachusetts. Neither this nor any other contact animal had traveled outside of the United States. This donkey had been clinically normal until skin lesions were noted eight months prior to euthanasia. Initially, skin lesions consisted of crusting on both flanks and the perivulvar area. Leukocytosis was present ( $12.89/\text{mm}^3$ , range 5.0–12.0  $\text{m}/\text{mm}^3$ ), total protein was elevated at 9.0 g/dL (range 5.7–8.0), and globulins were elevated at 6.0 g/dL (range 2.7–5.0). The donkey's hematocrit was just below normal at 31% (32–53% reference range). Right carpal lameness was noted at this time, and the animal was treated with SMZ (unknown dose) and tetracycline (2500 mg, orally, twice daily for 30 days). Lyme disease, bacterial arthritis and immune mediated arthritis were considered unlikely due to negative *Borrelia burgdorferi* antibody titers, synovial fluid culture, and anti-nuclear antibody serological testing, respectively.

One month after the onset of clinical signs, the donkey was suspected to have forelimb laminitis. Blood evaluation at this time revealed that the leukocyte counts were within normal range, protein levels were still elevated (total protein 9.5 g/dL, globulin 7.5 g/dL), and the hematocrit had dropped further to 26.7%. Approximately three months after the onset of clinical signs, protein levels were still elevated (total protein 8.9 g/dL, and globulins 6.6 g/dL), and the packed cell volume was further diminished at 25.2%. A repeat examination two months later revealed low albumin at 1.9 g/dL (range 2.2–3.7). Total protein was 8.4 g/dL and globulins were 6.5 g/dL. Haematocrit was low at 23%, and the leukocyte count was at the low end of the normal range at  $6.41/\text{mm}^3$ . The skin was biopsied approximately one month before euthanasia, which revealed a locally extensive, chronic fibrosing perivascular to

interstitial lymphoplasmacytic and granulomatous superficial dermatitis with intradermal *Besnoitia* tissue cysts. As the skin lesions progressed, the donkey became cachectic, and was euthanised.

#### 2.1.3. Donkey nos. 6 and 7

These animals were from the same farm as donkey no. 5. Donkey no. 6, an 11 year old female, had a three month history of progressive alopecia, erythema and crusting involving the face, neck, vulva, and lower leg regions. Donkey no. 7, a one year old female, had a similar history of alopecia and crusting that was confined to the muzzle and neck regions. Cutaneous besnoitiosis was diagnosed based on histologic examination of skin biopsy specimens from these animals. Both animals were originally treated for several months with SMZ, but Donkey no. 6 was eventually euthanised following a relapse of the skin lesions. Donkey no. 7 responded well to SMZ therapy. Treatment was continued with another antiprotozoal, Navigator paste (32% w/w nitazoxanide) for five days at 5 mg/kg followed by 23 days at 10 mg/kg (Idexx Laboratories, Inc., Westbrook, ME). Although clinical improvement was noted, *Besnoitia* tissue cysts and chronic inflammation were observed in follow-up skin biopsy specimens.

## 2.2. Infection of laboratory animals

Laboratory-reared gerbils, rabbit, mice, and cats were inoculated with *B. bennetti*. Animal experiments were performed according to Animal Care Protocols of the US Department of Agriculture.

The cats were from a parasite-free colony (Dubey, 1995). Muscles and skin heavily infected with tissue cysts from donkey no. 5 were fed to two cats. Faeces of cats were examined for coccidian oocysts by sugar flotation daily for 28 days thereafter (Dubey, 1995).

The five to eight week old female gerbils (*Meriones unguiculatus*) were obtained from Charles River Laboratory, Stoneridge, New York, USA. The 20–25 g female Swiss Webster (SW) out-bred mice were obtained from Taconic Farms, Germantown, New York, USA. The 5–10 week old female interferon-gamma gene knockout (KO) mice were obtained from Jackson Laboratories; these KO mice are highly susceptible to intracellular parasites because they lack the capacity to produce the cytokine interferon-gamma, necessary for killing of intracellular parasites (Dubey and Lindsay, 1998).

A skin biopsy from donkey no. 1 was homogenised in phosphate buffer saline (PBS) by mortar and pestle. The homogenate was sieved through gauze, centrifuged, resuspended in antibiotics (1000 units of penicillin and 100  $\mu\text{g}$  of streptomycin) and inoculated into animals (Table 1). Pieces of skin from donkey no. 5, containing numerous tissue cysts were homogenised in PBS, centrifuged, washed in antibiotic solution, and inoculated into animals (Table 1). The released bradyzoites were filtered through a 5- $\mu\text{m}$  filter,



Table 1  
Infectivity of *Besnoitia bennetti* to mice and gerbils

Source of inoculum	Animal species	No. inoculated	Inoculum	Route	Outcome <sup>a</sup>
Donkey no. 1	KO mice	4	Bradyzoites <sup>b</sup>	s.c.	<b>D57</b> , D75, K79, K79
		4	Bradyzoites <sup>b</sup>	i.p.	<b>D44</b> , <b>K44</b> , <b>K79</b> , <b>K79</b>
		5	Tachyzoites <sup>c</sup>	s.c., i.p.	<b>DK 21–36</b>
		3	Tachyzoites <sup>d</sup>	i.p.	<b>D19</b> , <b>D 29</b> , <b>D49</b>
		2	Tachyzoites <sup>c</sup>	s.c.	<b>DK35</b> , K36
		3	Tachyzoites <sup>c</sup>	i.p.	<b>DK21</b> , DK30, K36
	Gerbils	9	Bradyzoites <sup>b</sup>	s.c.	K36
		2	Tachyzoites <sup>c</sup>	i.p.	K36
		5	Bradyzoites <sup>b</sup>	s.c.	K79, K79
		5	Tachyzoites <sup>c</sup>	s.c., i.p.	K36
Donkey no. 5	KO mice	8	Bradyzoites <sup>b</sup>	s.c.	<b>DK41</b> , K53, K53, K53, <b>K45</b> , DK49, K48, K54
		4	Bradyzoites <sup>b</sup>	i.p.	<b>D18</b> , <b>D19</b> , <b>D52</b> , K 53
		3	Bradyzoites <sup>b</sup>	oral	K66
		2	Cloned bradyzoites 1 <sup>c</sup>	i.p.	<b>K24</b> , <b>D40</b>
		2	Cloned bradyzoites 2 <sup>c</sup>	i.p.	K45
		3	Bradyzoites <sup>f</sup>	s.c., i.p.	<b>K76</b> , K91, K91
		2	Tachyzoites <sup>c</sup>	s.c., i.p.	<b>DK27</b>
		3	Bradyzoites <sup>b</sup>	s.c., i.p., oral	K66
	Gerbils	3	Bradyzoites <sup>b</sup>	s.c., i.p., oral	K66

<sup>a</sup> D, Died; DK, Killed when sick; K, Killed when healthy. Parasites were demonstrated by histology only in the tissues of the animals indicated in bold.

<sup>b</sup> Homogenised tissue; number of organisms in inoculum unknown.

<sup>c</sup>  $1 \times 10^6$  tachyzoites from culture.

<sup>d</sup> Tachyzoites from mouse; number of organisms in inoculum unknown.

<sup>e</sup> Released from a single tissue cyst.

<sup>f</sup> Pepsin digested tissue; number of organisms in inoculum unknown.

and inoculated on to cell cultures and in mice and gerbils (Table 1). Pepsin digested (Dubey, 1998) material was inoculated s.c. and i.p. into KO mice (Table 1). Additionally, two individual tissue cysts were teased out from the fascia and the surrounding tissues were removed as much as possible. The cysts were further washed in antibiotic saline and ruptured using a 27-gauge needle. The released bradyzoites were inoculated i.p. separately into two groups of KO mice.

An eight week old New Zealand White rabbit (no. 65173) was inoculated s.c. and i.m. with  $1 \times 10^6$  cell culture-derived *B. bennetti* tachyzoites (isolate from donkey no. 1), and 40 days later with another dose of  $1 \times 10^6$  tachyzoites. The rabbit was bled and euthanised 68 days after the initial inoculation.

### 2.3. In vitro cultivation

Bradyzoites released from tissue cysts from donkey nos. 1 and 5 were filtered through a 5- $\mu$ m filter and seeded onto culture flasks containing monolayers of African Green Monkey (CV-1) cells, and M617 cells (Dubey et al., 2002). Monolayers of M617 cells were also infected with the peritoneal exudate of a KO mouse that was previously inoculated with the bradyzoites released from a single tissue cyst. To study parasite morphology, tachyzoites from cell cultures were seeded on to M617 cells grown on coverslips. Coverslips were removed at periodic intervals, fixed in Bouin's, stained with Giemsa, and examined

microscopically. Organisms were measured using the motorised system microscope (Olympus Optical Co., Tokyo, Japan) with an Olympus FV camera and Olympus Microsuite™ B3SV software.

### 2.4. Necropsy and histopathological examination

Samples of brain, lung, heart, tongue, liver, kidney, intestine, mesenteric lymph node, urinary bladder and limb muscle of gerbils, rabbit, mice, and cats were fixed in 10% neutral buffered formalin. Paraffin-embedded sections were cut at 5  $\mu$ m, and examined after staining with H&E or periodic acid Schiff reaction counter stained with haematoxylin (PASH).

### 2.5. Transmission electron microscopy

For TEM, tissues were fixed in glutaraldehyde or in 10% buffered neutral formalin. They were subsequently post-fixed in osmium and processed for TEM. For the study of tachyzoites, M617 cells infected in vitro and the skin of a KO mouse inoculated with the isolate from donkey no. 5, 45 days p.i were used.

### 2.6. Immunohistochemical staining

Two types of primary antibodies were used for immunohistochemical staining. A polyclonal anti-*B. bennetti* antibody from rabbit No. 65173 was used at 1:500–1:8000 serum

dilutions and a bradyzoite-specific rabbit antibody (BAG-1, also called BAG-5) directed against a heat-shock protein from *Toxoplasma gondii* (supplied by McAllister et al., 1996) was used at 1:10,000 serum dilution. Staining was performed as described previously (Dubey and Sreekumar, 2003).

### 2.7. Serologic examination

Using tachyzoites grown in M617 cells and rabbit anti-horse IgG whole molecule FITC conjugate (Sigma, St Louis, MO, USA) at 1:50 dilution indirect fluorescent antibody testing (IFAT) was used to detect antibodies to *B. bennetti* in sera of four donkeys.

### 2.8. Molecular systematics

DNA from *B. bennetti* tachyzoites of isolates from donkey nos. 1 and 5 was extracted by proteinase K digestion, and purification using Qiagen DNAeasy columns according to the manufacturer's protocol. Aliquots along with extraction negatives, were subsequently used as templates in PCR assays to characterise a 1961 bp portion of ribosomal DNA encompassing most of the *ssrDNA* as well as the first internal transcribed spacer 1 (ITS-1), and a 1912 bp portion of the *lsrDNA* using previously described methods (Dubey et al., 2004). These products were directly sequenced on an ABI 3100 fluorescent sequencer using BigDye 3.1 terminator chemistries. Sequence contigs were assembled and edited using ContigExpress (VectorNTI, Informax Inc.) and compared with other homologues by means of Neighbor Joining trees reconstructed from Kimura 2-parameter distances from 500 bootstrap replicates of multiple sequence alignments created using CLUSTALW, as implemented by MEGA version 2.0 (Kumar et al., 2001). The phylogenetic position of *B. bennetti* was placed in a broad comparative framework by inclusion of other available sequences of *lsrDNA* from diverse species belonging to the Sarcocystidae; by limiting a subsequent analysis to members of the genus *Besnoitia*, we were able to more precisely define its phylogenetic position with respect to its closest relatives using a longer portion of ungapped alignment.

## 3. Results

### 3.1. Lesions in donkeys

Gross skin lesions in donkey no. 5 consisted of multifocal to coalescing areas of patchy alopecia and hypotrichosis, with thickened, irregular crusty hyperpigmented skin of the neck, around the muzzle, eyes, base of the ears, over the carpus, elbow, stifle, tarsus, extending over the cannon bones to the pastern and fetlocks of all four limbs and over the perineum (Fig. 1 (B–D)). Within the affected dermis and epidermis, hundreds of pinpoint white granular structures

were present, ranging from 0.5 to 1.5 mm in diameter. The subcutaneous tissues and superficial fascia under the affected skin, as well as the scleral conjunctiva and vaginal mucosa, contained millions of white granules ranging from 0.5 to 1.5 mm in diameter. The prescapular, mandibular, and popliteal lymph nodes were diffusely enlarged, ranging from  $2 \times 2 \times 3$  to  $8 \times 3 \times 2$  cm<sup>3</sup>. Lymphoid tissue surrounding the larynx and pharynx was noted to be hyperplastic.

The donkey as a whole was markedly cachectic, with minimal fat stores, and serous atrophy of fat at the base of the heart. The distal phalanges of the left and right forelimb and right hind limb were ventrally rotated 35, 20, and 40°, respectively, from the hoof wall. At the ileocecolic junction, approximately 20 tapeworms (*Anoplocephala perfoliata*) were present.

Histologically, in all skin sites examined, numerous *Besnoitia* tissue cysts were present within the dermis, panniculus, and underlying muscle. The skin crust consisted of desquamated host tissues as well as numerous free bradyzoites (Fig. 2). A moderate multifocal perivascular to interstitial chronic fibrosing lymphoplasmacytic, histiocytic, and eosinophilic dermatitis and myositis accompanied the tissue cysts (Fig. 2). Multifocal sites of tissue cyst rupture incited a severe acute neutrophilic, eosinophilic and lymphoplasmacytic dermatitis. Within the superficial dermis, moderate, multifocal perivascular lymphoplasmacytic infiltrates were present.

The vulvar mucosa contained large numbers of *Besnoitia* tissue cysts with characteristics similar to those described above throughout the lamina propria and muscularis. A mild to moderate multifocal perivascular to interstitial chronic fibrosing lymphoplasmacytic, histiocytic, and eosinophilic vulvitis and myositis accompanied the cysts. Multifocal sites of tissue cyst rupture created a severe acute neutrophilic, lymphoplasmacytic, histiocytic and eosinophilic vulvitis.

*Besnoitia* sp. tissue cysts were present within the sclera and iris, the right thyroid gland and perithyroid and perilaryngeal connective tissue and were associated with inflammation in these tissues. Severe, diffuse, chronic reactive lymphoid hyperplasia and moderate diffuse sinus histiocytosis were present in all peripheral lymph nodes examined. A moderate, multifocal to coalescing subacute to chronic lymphoplasmacytic interstitial pneumonia with mild multifocal neutrophilic and histiocytic alveolar septal infiltrates, and moderate, multifocal subacute pulmonary and pleural oedema were present. Within the colon, a severe, focal chronic submucosal lymphoid hyperplasia was present, with an adjacent histiocytic and lymphoplasmacytic colitis.

The kidney contained evidence of mild multifocal acute tubular necrosis, and multifocal moderate chronic lymphoplasmacytic and histiocytic interstitial nephritis. Within the brain, more commonly in the rostral than caudal aspects, multifocal areas of lymphohistiocytic perivascular cuffing

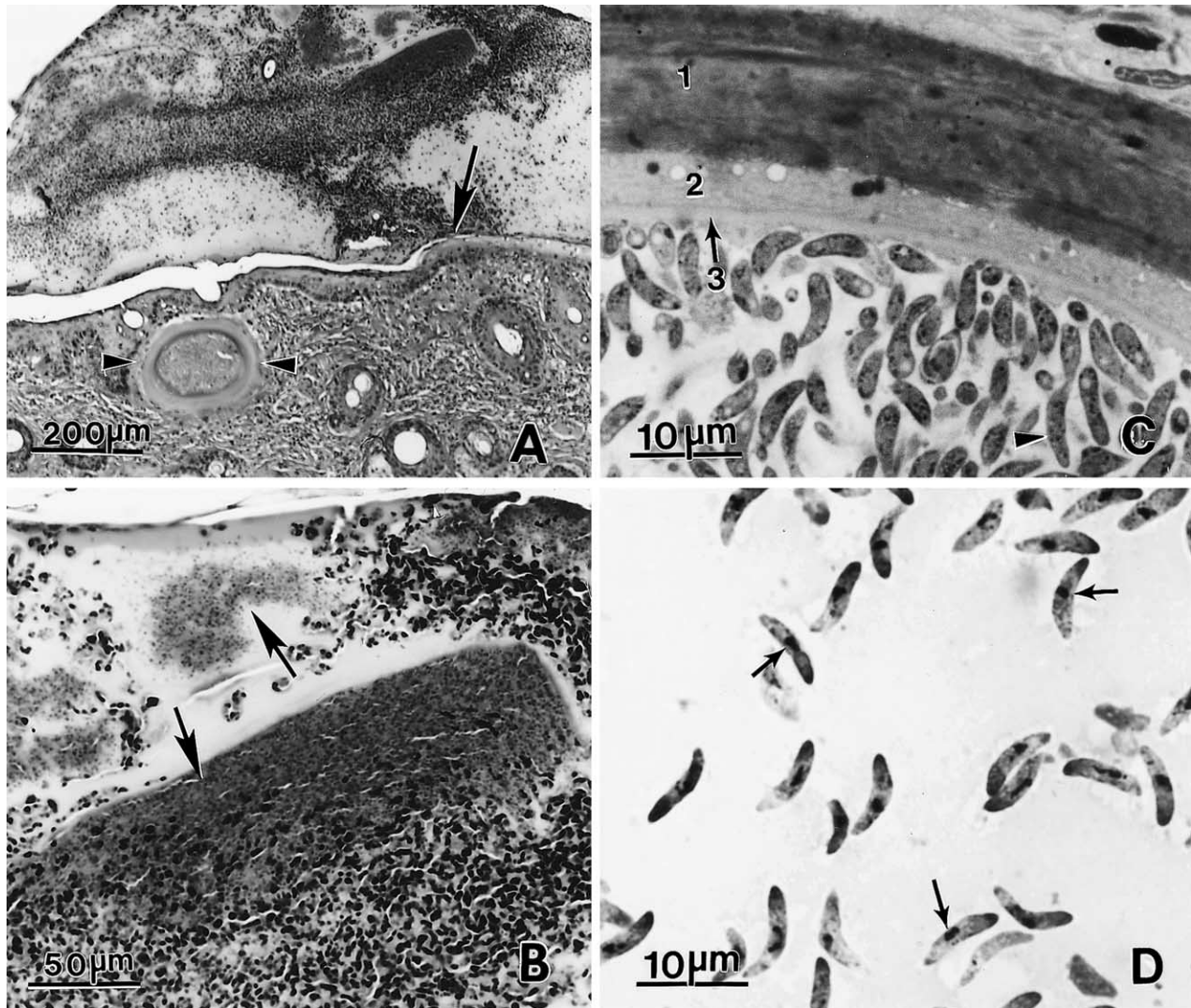


Fig. 2. *Besnoitia bennetti* and associated lesions in skin of donkey no. 5. (A) A crust containing desquamated host tissue and bradyzoites, attached to epidermis (arrow). An intact tissue cyst is in the dermis (arrowheads). H&E. (B) Bradyzoites (arrows) among degenerating host tissue. H&E. (C) Section of a tissue cyst. There are three layers, outer (1) thick layer, a middle layer (2) and a third (3) thin layer. 1  $\mu$ m section stained with toluidine blue. Numerous bradyzoites (arrowheads) are enclosed in layer 3. (D) Bradyzoites (arrows) released from a tissue cyst in a smear stained with Giemsa.

were present. The liver had a moderate, diffuse haemosiderosis.

### 3.2. Structure of tissue cysts and bradyzoites

Tissue cysts were located in the skin, subcutaneous tissue, conjunctiva, sclera, occasionally in soft tissues (Fig. 1). They were white to glistening white to the naked eye and embedded in host tissue. Tissue cysts were up to 400  $\mu$ m long and the cyst walls were up to 40  $\mu$ m thick (Fig. 2). The thickness of the tissue cyst wall varied. Under the light microscope three layers were recognised. The outer layer (layer 1) consisted of hyaline connective tissue; it stained weakly positive with PASH. The middle layer (layer 2) enclosed host cell elements including host cell nuclei; it stained intensely with PASH. The innermost layer (layer 3, the parasitophorous vacuolar membrane (PVM) was less

than 1  $\mu$ m thick; it was PAS-negative. Numerous PAS-positive bradyzoites were enclosed in layer 3. The bradyzoites released from four tissue cysts were  $8.7 \times 1.9 \mu\text{m}$  ( $7.0\text{--}11.9 \times 1.2\text{--}2.8$ ,  $n=100$ ). Longitudinally cut bradyzoites in 1- $\mu$ m Toluidine blue sections from four tissue cysts were  $7.8 \times 1.7 \mu\text{m}$  ( $5.8\text{--}10.3 \times 1.1\text{--}2.3$ ,  $n=100$ ). Tissue cysts were not septate. Occasionally, two tissue cysts were enclosed in the same host cell (Fig. 3), giving the false impression of septa.

The three layers seen under light microscopy were also recognised by TEM. The outer layer consisted of connective tissue. The middle layer contained host cell nuclei and an accumulation of endoplasmic reticula; filamentous extensions were seen that projected towards the outer most layer. The innermost layer consisted of a thin PVM, which was lined by an amorphous granular layer, which varied in thickness. Numerous bradyzoites were enclosed in



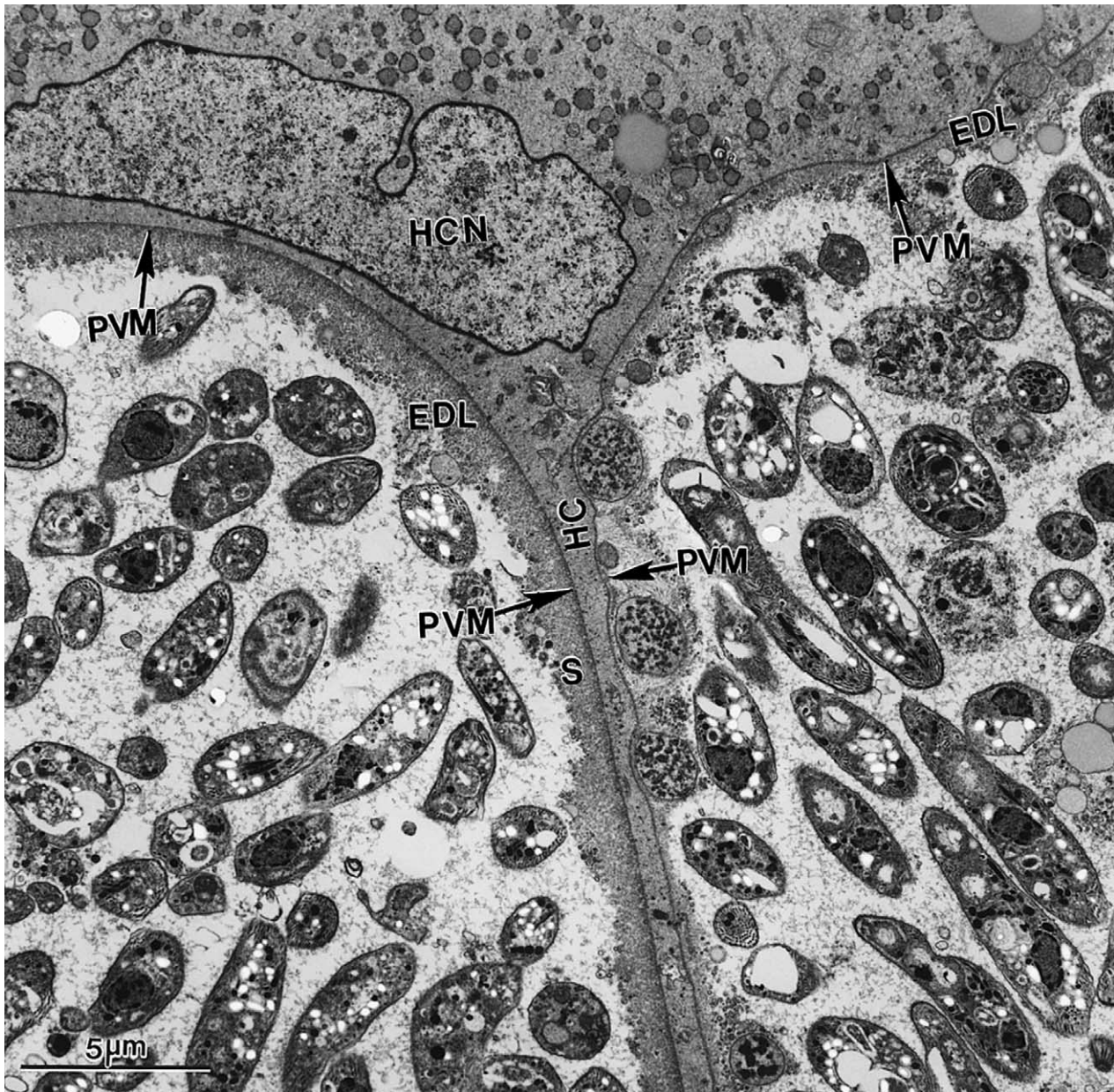


Fig. 3. TEM of two tissue cysts enclosed in the same host cell (HC), giving the false impression of a septum. Note a thin layer of host cell material (HC) between two tissue cysts. Also note the host cell nucleus (HCN), and parasitophorous vacuolar membrane (PVM) and electron dense layer (EDL) of the separate tissue cysts.

the granular layer. Bradyzoites varied in size and shape (Figs. 3 and 4), some were plump whereas others were slender (Fig. 4). Ten longitudinally cut bradyzoites were  $4.9\text{--}8.5.0 \times 1.19\text{--}1.70 \mu\text{m}$  in size on TEM sections. Bradyzoites contained a conoid, micronemes, rhoptries, a nucleus, amylopectin, a mitochondrion and dense granules. Micronemes were numerous (up to 100 per section) and were located throughout the bradyzoite but were more numerous at the conoidal end. They were up to 570 nm long and approximately 50 nm wide. The rhoptries extended up to the posterior end (Fig. 4). The contents of rhoptries were electron-dense. The bulbous end of rhoptries was up to

400 nm wide. Occasionally, the bulbous end was turned towards the conoidal end of the bradyzoite (Fig. 4B). A maximum of five rhoptries were seen in a given section. The position of the nucleus in bradyzoites was central to terminal (Fig. 4). The amylopectin granules were located throughout the bradyzoite. Enigmatic bodies were not found in any of the bradyzoites examined from four tissue cysts (Fig. 4).

### 3.3. Isolation of *B. bennetti* in cell culture

Tachyzoites were seen in the M617 monolayer 43 days after inoculation with bradyzoites from donkey no. 1.



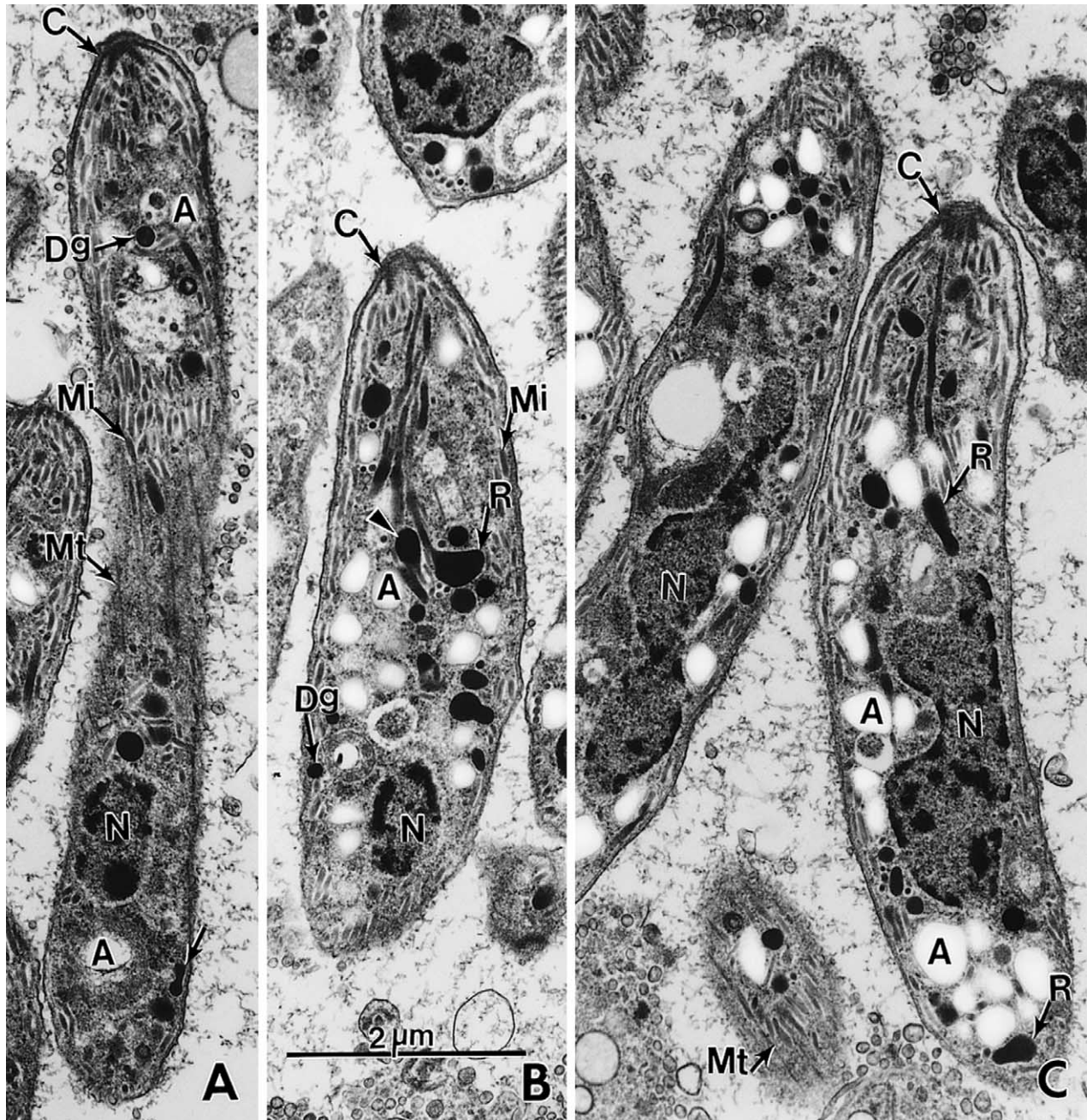


Fig. 4. TEM of *Besnoitia bennetti* bradyzoites of different shapes and sizes (A, B, C). Bar in B applies to all parts. Note conoid (C), dense granules (Dg), microtubules (Mt), micronemes (Mi), amylopectin (A, empty spaces), rhoptries (R), and different shapes, location, and sizes of nucleus (N). Also note that the bulbous end of one rhoptry (arrowhead in B) is pointed towards the conoidal end.

The monolayer was completely destroyed in 56 days and the tachyzoites were continuously passaged. The growth rate of the tachyzoites in vitro was slow and the average passage interval was more than 60 days despite using a large inoculum of more than  $10^5$  tachyzoites. Though occasional dividing forms were initially noticed, the parasite never established itself in the CV1 monolayers and the cultures were discarded after 63 days.

The tachyzoites from the peritoneal exudate of a KO mouse that was infected with bradyzoites from a single

tissue cyst (cloned isolate) was established in M617 monolayers and was passaged continuously. The tachyzoites from the first passage were cryopreserved for future use.

In coverslip cultures, stray intracellular parasites could be seen in the coverslips stained 4 h after inoculation. By 48 h, numerous cells with two, four and eight parasites could be seen (Fig. 5F). Spontaneous ingress of parasites from intact cells was noticed. Numerous plaques, surrounded with parasitised cells and numerous extracellular



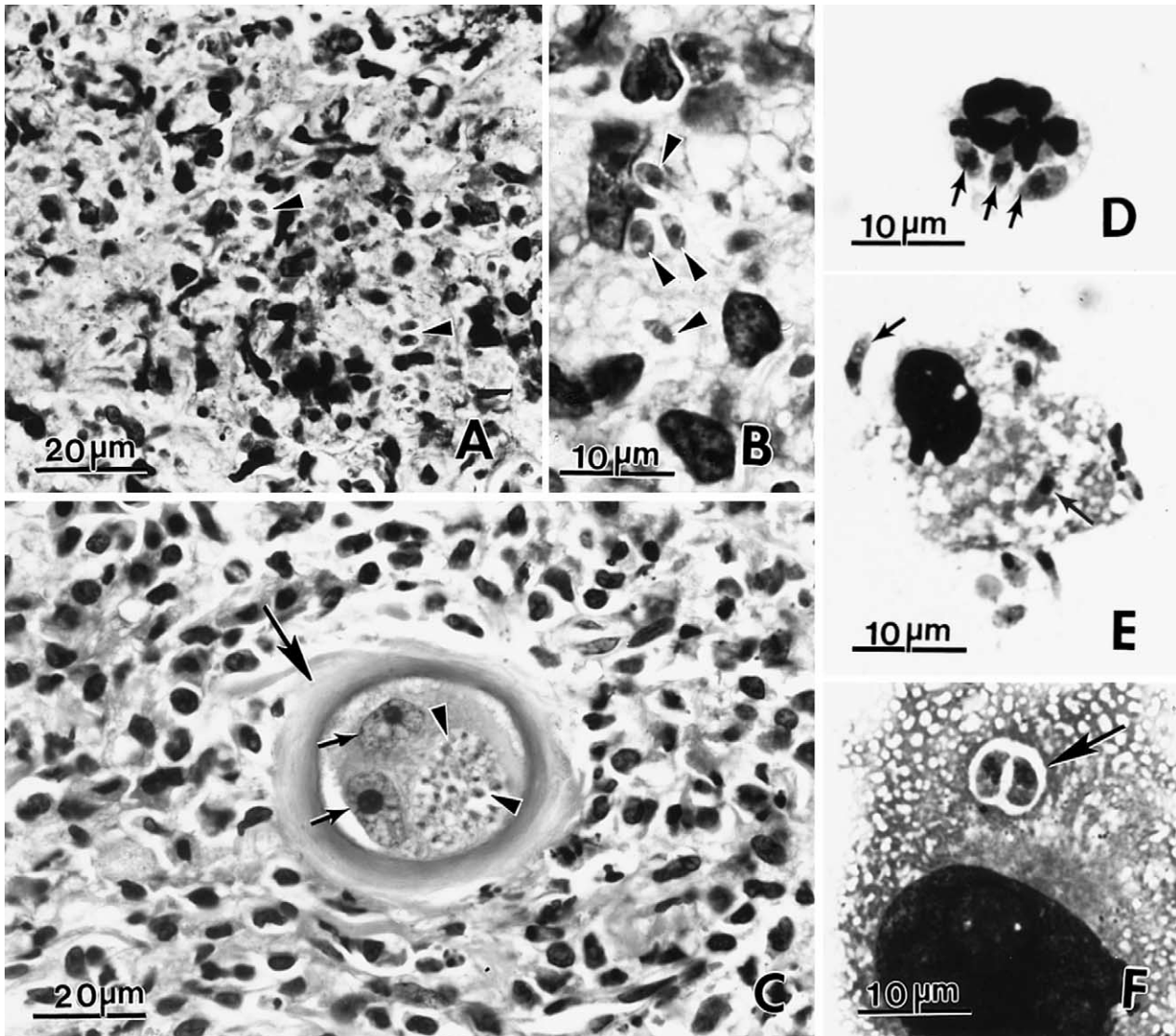


Fig. 5. *Besnoitia bennetti* stages. (A–E) from KO mice and (F) from cell culture. (A and B) section of cutaneous granuloma with faintly stained tachyzoites (arrowheads). 45 days p.i. H&E. (C) Section of eye with a tissue cyst (arrow) in periorbital granuloma. Note a thick walled tissue cyst enclosing two host cell nuclei (small arrows) and bradyzoites (arrowheads). This was the only tissue cyst found in all KO mice inoculated with *B. bennetti*, 45 days p.i. (D) Three tachyzoites with dividing nuclei (arrows) inside a neutrophil from smear of peritoneal exudate of KO mouse, 45 days p.i. Giemsa stain. (E) Lunate tachyzoites (arrows) in and out of a macrophage from the same mouse as in Fig. 6D. Giemsa stain. (F) Two tachyzoites within one parasitophorous vacuole (arrow) in M617 cell 48 h p.i. Giemsa stain.

tachyzoites, were observed after 27 days. The monolayer was destroyed in 43 days.

Extracellular tachyzoites from cell culture were  $5.9 \times 1.6 \mu\text{m}$  ( $5.0\text{--}7.3 \times 1.1\text{--}2.5$ ,  $n = 50$ ).

#### 3.4. Ultrastructure of tachyzoites

Tachyzoites were located in a parasitophorous vacuole containing tubular network, in the host cell cytoplasm of neutrophils, mononuclear cells, and fibroblasts in subcutaneous tissue of the mouse (Fig. 6). Tachyzoites divided by endodyogeny. They contained a conoid, several micronemes, rhoptries, an elongated mitochondrion, a nucleus,

but no amylopectin granules (Fig. 6). The micronemes were located anterior to the nucleus and often arranged in rows (Fig. 6). The number of micronemes was highly variable from a few (Fig. 6C) to numerous (Fig. 6B). The rhoptries were few in number and their contents were electron-dense.

#### 3.5. Serologic examination

The IFAT titers of the donkey nos. 1–4 were 1:5000, 1:1600, 1:800, 1:200, respectively, suggesting exposure to *B. bennetti*; donkey no. 1 had clinical besnoitiosis. The IFAT titers of the seven horses were 1:800 in one, 1:400 in one, and 1:200 or less in five horses.

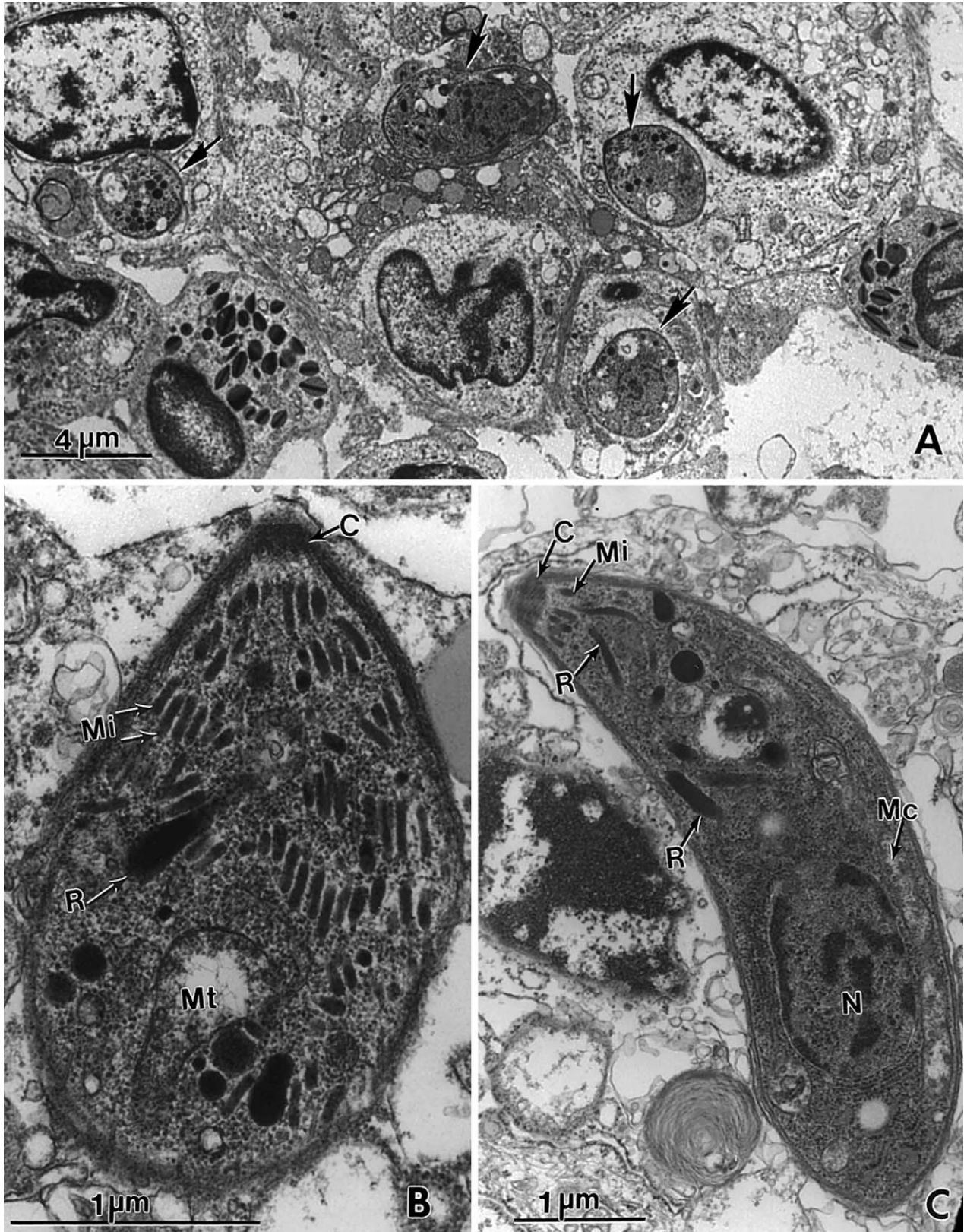


Fig. 6. TEM of *Besnoitia bennetti* tachyzoites. (A, B) Individual tachyzoites (arrows) in dermal tissue of a KO mouse 45 days p.i. and (C) from cell culture. Note conoid (C), micronemes (Mi), rhoptries (R), an elongated mitochondrion (Mc), and a nucleus (N).



### 3.6. Immunohistochemistry

The innermost layer (third layer) and the enclosed bradyzoites in tissue cysts stained positively with anti-*B. bennetti* antibodies up to 1:8000 serum dilution. However, tachyzoites in tissue sections of KO mice were stained only at 1:500 dilution. Bradyzoites, but not the tachyzoites, were stained with BAG-1-antibodies.

### 3.7. Infection of laboratory animals

No oocysts were seen in faeces of cats nor were any protozoa identified in their histological sections.

Protozoa were not identified in tissues of any of the gerbils or out-bred mice (Table 1), whether inoculated with donkey tissues or with tachyzoites derived from cell culture or from KO mice. The KO mice inoculated with bradyzoites or tachyzoites became infected but the organisms were not demonstrable in all mice (Table 1). Cutaneous granulomas developed at the injection site in mice inoculated subcutaneously, and tachyzoites were present in these lesions (Fig. 5B and C). The i.p. inoculated mice developed ascites that contained white fluid and tachyzoites were present in the fluid. *Besnoitia* were not seen in liver, lungs, brain, and the heart. Only tachyzoites were identified in all infected mice except in periorbital tissue of a KO mouse that had been inoculated subcutaneously with bradyzoites from donkey no.1; a small tissue cyst was present in this mouse (Fig. 5C).

Protozoa were not identified in tissues of the rabbit inoculated with tachyzoites from cell culture.

### 3.8. Molecular systematics

The sequences of *ssrDNA* of *B. bennetti* were compared with those of other *Besnoitia* sp., as well as other apicomplexans. The 1961 bp of small subunit rDNA (GenBank AY827838) and ITS-1 (GenBank AY827839) were identical to those derived from an isolate of *B. bennetti* from a miniature donkey in Michigan (GenBank accession AY665399, Elsheikha et al., 2005). The 1912 bp of large subunit rDNA of each of two isolates described here were identical to each other and were inferred to be closely related to other tissue cyst forming coccidia (Fig. 7). This sequence has been deposited as GenBank accession AY778965.

### 3.9. Effect of chemotherapy

Donkey no.1 had remarkable clinical improvement after a seven month treatment with SMZ and TM (Fig. 1E). All tissue cysts seen in the biopsy of the only grossly visible lesions on the muzzle were degenerated and mineralised.

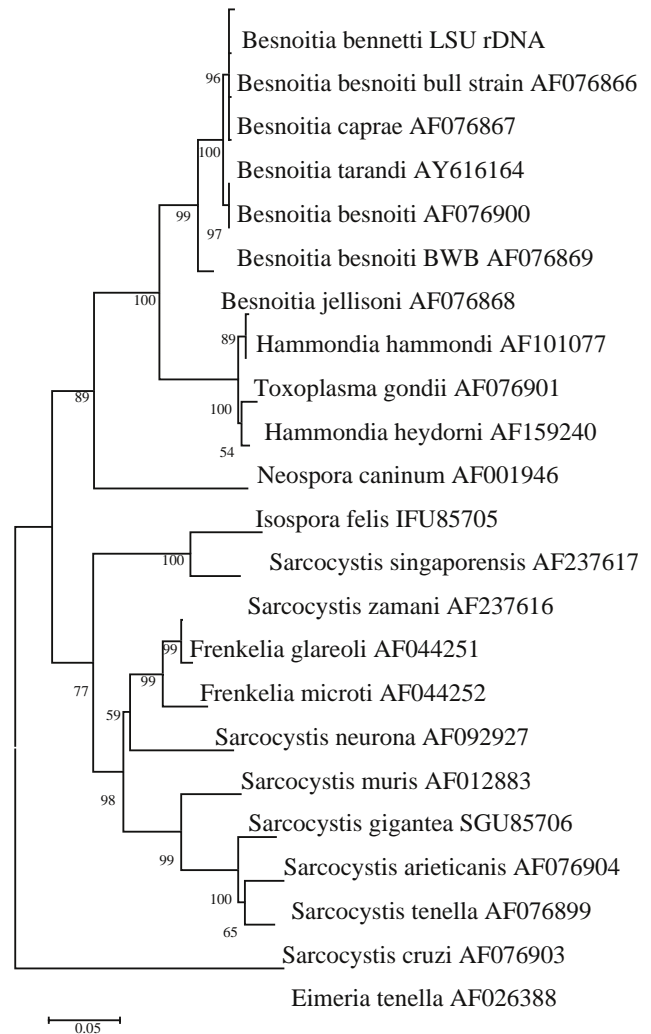


Fig. 7. Placement of species of *Besnoitia* within a large phylogenetic context reconstructed from *lsurDNA*. Midpoint-rooted neighbor joining tree reconstructed from 500 bootstrap resamplings of 503 ungapped positions of nuclear large subunit ribosomal DNA gene using Kimura 2-parameter distances.

### 3.10. Taxonomic summary

Intermediate type hosts: Equids (*Equus caballus*, *Equus asinus*)

Definitive host: Unknown.

Locality: USA, Africa.

*Specimens deposited* Specimens were deposited in the United States National Parasite Collection (USNPC), United States Department of Agriculture, Beltsville, MD, USA: (a) histologic sections of tissue cysts from subcutaneous tissue of donkey no.5 stained with H&E (USNPC No. 95254), (b) stained with anti-*B. bennetti* antibodies (USNPC No. 95255), (c) 1- $\mu$ m section stained with Toluidine blue (USNPC No. 95256) and (d) unstained tissue in 10% buffered neutral formalin (USNPC No. 95257), (e) histologic sections of tissues of a KO mice experimentally-infected with cell-culture derived

*B. bennetti* tachyzoites, 45 days p.i., stained with H&E (USNPC No. 95258), and (f) *B. bennetti* tachyzoites in cell culture preparations of M617 cells stained with Giemsa (USNPC No.95259).

Live cultures of tachyzoites of *B. Bennettii* (from donkey no.5) were deposited in the American Type Culture Collection (ATCC), Manassas, VA 20108, USA, ATCC Accession No. PRA-145.

#### 4. Discussion

In general, the structure of tissue cysts of *B. bennetti* found in the present study is similar to that of *B. oryctofelisi*. Dubey and Lindsay (2003) described the development and structure of *B. oryctofelisi* tissue cysts in experimentally-infected animals. They provided evidence that the outer two layers of the tissue cyst walls were of host origin, as they did not stain with the *B. oryctofelisi* antibodies. However, the inner (third) layer and the bradyzoites were stained with the antibodies indicating parasitic origin. The immunohistochemical staining results with anti-*B. bennetti* polyclonal serum in the present study, confirms the findings of Dubey and Lindsay (2003). Why *B. bennetti* tachyzoites in sections of mice had a lower reactivity (positive at 1:500) to anti-*B. bennetti* antibodies than bradyzoites in tissue cysts is unexplained because the polyclonal serum was against tachyzoites.

Until recently, enigmatic bodies, first described in *Besnoitia jellisoni* by Sénaud (1969), were considered characteristic for *Besnoitia* spp. bradyzoites. They contain a central core enclosed in a membrane; their function is unknown. However, extensive studies failed to identify enigmatic bodies in bradyzoites of *B. besnoiti* of cattle (Dubey et al., 2003b), nor were they previously observed in *B. bennetti* from a horse in South Africa (van Heerden et al., 1993). No enigmatic bodies were identified in bradyzoites of *B. bennetti* from donkeys we studied here, nor were they reported in either of the two ultrastructural studies of Canadian reindeer *Besnoitia* species (Glover et al., 1990; Ayroud et al., 1995).

In *B. bennetti*, the rhoptries were as long as the bradyzoites and in some, the bulbous end was directed towards the conoidal end instead of the non-conoidal end. This is the second report of this feature of rhoptries of *Besnoitia*. We previously found this feature in rhoptries of *B. tarandi* (Dubey et al., 2004). Ultrastructurally, *B. bennetti* bradyzoites appeared to possess ~100 micronemes. This is in contrast to the higher number of micronemes (~300) found in the bradyzoites of *B. darlingi* (Dubey et al., 2002), *B. oryctofelisi* (Dubey et al., 2003a), and *Besnoitia akodoni* (Dubey et al., 2003c).

Cutaneous besnoitiosis attributed to *B. besnoiti* causes substantial economic loss among cattle in Africa, Israel, and some parts of Europe (Dubey et al., 2003a). Although besnoitiosis in goats was presumed to be caused by a distinct

taxon, *Besnoitia caprae*, an absence of diagnostic variation in the ITS-1 between caprine isolates and those from cattle and wildebeest has questioned this distinction (Ellis et al., 2000). In order to verify the placement of the *B. bennetti* isolate within a monophyletic group comprising other named *Besnoitia* congeners, and in order to evaluate the degree to which it could be differentiated from such congeners, three portions of nuclear ribosomal DNA were characterised and compared with other available homologues. Including this report, a total of three isolates of *B. bennetti* have been characterised at a portion of small subunit and ITS-1 rDNA comprising some 1960 base pairs. The absolute uniformity of these isolates, originating in Vermont, Florida, and Michigan, preliminarily suggests that donkey parasites inducing clinical besnoitiosis are con-specific. As this sequence differs, if only slightly, from homologues of congeneric parasites, we conclude that this sequence may be useful in future diagnoses. Previous phylogenetic analyses (Dubey et al., 2004) have also supported the monophyly of the genus *Besnoitia* and indicated a particularly close relationship between parasites of cattle, goats, caribou, and equids (*B. besnoiti*, *B. caprae*, *B. tarandi*, and *B. bennetti*) with the exclusion of other congeners that parasitise rodents, lagomorphs, and opossums (*B. jellisoni*, *B. akodoni*, *B. oryctofelisi*, and *B. darlingi*).

Our new analysis of lsrRNA confirms previous conclusions based upon other genetic loci (Dubey et al., 2004; Elsheikha et al., 2005) that the genus *Besnoitia* is monophyletic with the exclusion of other tissue cyst forming coccidia, and that they form a sister group to the one containing species assigned to the genera *Toxoplasma*, *Neospora*, and *Hammondia*. Additionally, our analysis indicates that the genus *Besnoitia* includes distinct lineages, one of which has given rise to the parasites of ungulates, *B. besnoiti*, *B. tarandi*, *B. caprae*, and *B. bennetti*. Whether the parasite in horses is the same as the parasite in donkeys requires further study; notably, *B. bennetti* infection has not been reported in horses in the USA. If future studies determine a distinct phylogenetic difference between the parasite of horses and donkeys, a new name for the donkey parasite would be required.

In the present study, donkey no. 1 improved clinically and all tissue cysts were dead after a seven month treatment with SMZ and TM. Somewhat similar results were reported by Davis et al. (1997) in a donkey that was medicated with SMZ for 30 days, discontinued for 30 days, and then treated for an additional 30 days; this treatment resolved pruritic dermatitis but results were not confirmed by biopsy. Although these studies are uncontrolled, they do suggest that treatment with SMZ can reduce suffering from besnoitiosis. To our knowledge this is the first documented killing of *Besnoitia* tissue cysts after treatment with any anti-protozoal therapy.

Developing adequate laboratory models would promote the study of the biology and epidemiology of ungulate



besnoitiosis. Tissue cysts of *B. bennetti* have not yet been produced in laboratory animals or in cell culture. A single tissue cyst was found in an infected KO mouse in this study. Gerbils that are susceptible to experimental infections with other species of *Besnoitia* (*B. darlingi*, *B. besnoiti*, *B. oryctofelisi*, and *B. jellisoni*) do not become infected by *B. bennetti* and *B. tarandi*. Limited trials have also revealed that, whereas rabbits are refractive to infection with *B. tarandi*, *B. bennetti* and *B. darlingi*, they could be infected with *B. besnoiti* and *B. oryctofelisi*. Out-bred Swiss Webster mice were also refractive to infection with *B. tarandi* and *B. bennetti*. Unlike other *Besnoitia* species, even KO mice were not highly susceptible to *B. bennetti*.

Tachyzoites of *B. bennetti* were found to multiply much slower in vitro than those of *B. darlingi*, *B. oryctofelisi*, *B. akodonii* and *B. tarandi*. The passage interval was more than 60 days, which is considerably higher. Furthermore, we were unable to establish *B. bennetti* in CV1 cells, which support the growth of *B. darlingi*, *B. oryctofelisi*, *B. akodonii* and *B. tarandi*.

Domestic cats serve as definitive hosts for the three species of *Besnoitia* whose life cycles are known (*B. darlingi*, *B. oryctofelisi* and *B. wallacei*). Results of the present study indicate that domestic cats are not likely to play this role for *B. bennetti*. Epidemiologic evidence argues against congenital transmission of *Besnoitia* species. The mode of infection in equids remains a mystery; transmission by large members of Felidae (cougars, lynx) remains a possibility. Glover et al. (1990) observed an inverse correlation between transmission of *Besnoitia* and exposure to biting flies, among reindeers. The presence of numerous extracellular bradyzoites in the dermal crust in the present study lends credence to the hypothesis that arthropods might play a role in the transmission of besnoitiosis. In the present study, only three of 150 donkeys on a farm had clinical besnoitiosis but the exposure rate was unknown. Finding of antibodies to *B. bennetti* in three of three donkeys and at least two of the seven horses without any clinical signs suggests that *Besnoitia* infection may be more common in equids in the USA than realised. However, serological results are preliminary because we did not have access to sera from donkeys not exposed to *B. bennetti*. Besnoitiosis in donkeys causes economic losses. Hence it is essential to have a better understanding of the biology and life cycle of this parasite, including the possible definitive host(s), to formulate adequate control measures.

## Acknowledgements

We would like to thank John Jenkins, Armed Forces Institute of Pathology, Washington, D.C., for the electron micrographs, O.C.H. Kwok, USDA, for his assistance with the cell culture, Detiger Dunams for her assistance

with the genetic analysis, Drs Clive Huxtable, Ana Alcaraz and Emily Meseck for diagnostic work and photography, Dr Keith Beebe and Mr Martin Ross for photographs and facilitation of the necropsy procedure of donkey no. 5, Dr M. S. Rose for clinical information on donkeys 6 and 7, and Ms Marcy Freedman for help with investigations on donkey nos. 1–4.

## References

- Ayroud, M., Leighton, F.A., Tessaro, S.V., 1995. The morphology and pathology of *Besnoitia* sp. in reindeer (*Rangifer tarandus tarandus*). J. Wildlife Dis. 31, 319–326.
- Babudieri, B., 1932. Sarcosporidi e le sarcosporidiosi (Studio monografico). Arch. Protistenkd. 76, 421–580.
- Bennett, S.C.J., 1927. A peculiar equine sarcosporidium in the Anglo-Egyptian Sudan. Vet. J. 83, 297–304.
- Bennett, S.C.J., 1933. *Globidium* infections in the Sudan. J. Comp. Pathol. Thera. 46, 1–15.
- Bigalke, R.D., 1970. Studies on equine besnoitiosis. J. Parasitol. 56, 29.
- Davis, W.P., Peters, D.F., Dunstan, R.W., 1997. Besnoitiosis in a miniature donkey. Vet. Dermatol. 8, 139–143.
- Dubey, J.P., 1995. Duration of immunity to shedding of *Toxoplasma gondii* oocysts by cats. J. Parasitol. 81, 410–415.
- Dubey, J.P., 1998. Refinement of pepsin digestion method for isolation of *Toxoplasma gondii* from infected tissues. Vet. Parasitol. 74, 75–77.
- Dubey, J.P., Lindsay, D.S., 1998. Isolation in immunodeficient mice of *Sarcocystis neurona* from opossum (*Didelphis virginiana*) faeces, and its differentiation from *Sarcocystis falcatula*. Int. J. Parasitol. 28, 1823–1828.
- Dubey, J.P., Lindsay, D.S., 2003. Development and ultrastructure of *Besnoitia oryctofelisi* tachyzoites, tissue cysts, bradyzoites, schizonts and merozoites. Int. J. Parasitol. 33, 807–819.
- Dubey, J.P., Sreekumar, C., 2003. Redescription of *Hammondia hammondi* and its differentiation from *Toxoplasma gondii*. Int. J. Parasitol. 33, 1437–1453.
- Dubey, J.P., Lindsay, D.S., Rosenthal, B.M., Sreekumar, C., Hill, D.E., Shen, S.K., Kwok, O.C.H., Rickard, L.G., Black, S.S., Rashmir-Raven, A., 2002. Establishment of *Besnoitia darlingi* from opossums (*Didelphis virginiana*) in experimental intermediate and definitive hosts, propagation in cell culture, and description of ultrastructural and genetic characteristics. Int. J. Parasitol. 32, 1053–1064.
- Dubey, J.P., Sreekumar, C., Lindsay, D.S., Hill, D., Rosenthal, B.M., Venturini, L., Venturini, M.C., Greiner, E.C., 2003a. *Besnoitia oryctofelisi* n. sp. (Protozoa: Apicomplexa) from domestic rabbits. Parasitology 126, 521–539.
- Dubey, J.P., Shkap, V., Pipano, E., Fish, L., Fritz, D.L., 2003b. Ultrastructure of *Besnoitia besnoiti* tissue cysts and bradyzoites. J. Eukaryot. Microbiol. 50, 240–244.
- Dubey, J.P., Sreekumar, C., Rosenthal, B.M., Lindsay, D.S., Grisard, E.C., Vitor, R.W.A., 2003c. Biological and molecular characterization of *Besnoitia akodonii* n. sp. (Protozoa: Apicomplexa) from the rodent *Akodon montensis* in Brazil. Parasitologia 45, 61–70.
- Dubey, J.P., Sreekumar, C., Rosenthal, B.M., Vianna, M.C.B., Nylund, M., Nikander, S., Oksanen, A., 2004. Redescription of *Besnoitia tarandi* (Protozoa: Apicomplexa) from the reindeer (*Rangifer tarandus*). Int. J. Parasitol. 34, 1273–1287.
- Ellis, J.T., Holmdahl, O.J.M., Ryce, C., Njenga, J.M., Harper, P.A.W., Morrison, D.A., 2000. Molecular phylogeny of *Besnoitia* and the genetic relationships among *Besnoitia* of cattle, wildebeest and goats. Protistologia 151, 329–336.

- Elsheikha, H.M., Mackenzie C.D., Rosenthal, B.M., Marteniuk J.V., Steficek, B., Windsor, S., Saeed, A.M., Mansfield, L.S., An outbreak of besnoitiosis in miniature donkeys. *J. Parasitol.* in press.
- Glover, G.J., Swendrowski, M., Cawthorn, R.J., 1990. An epizootic of besnoitiosis in captive caribou (*Rangifer tarandus caribou*), reindeer (*Rangifer tarandus tarandus*), and mule deer (*Odocoileus hemionus hemionus*). *J. Wildlife Dis.* 26, 186–195.
- Kumar, S., Tamura, K., Jakobsen, I.B., Nei, M., 2001. MEGA2: molecular evolutionary genetics analysis software. *Bioinformatics* 17, 1244–1245.
- Lane, J.G., Lucke, V.M., Wright, A.I., 1986. Parasitic laryngeal papillomatosis in a horse. *Vet. Rec.* 119, 591–593.
- McAllister, M.M., Parmley, S.F., Weiss, L.M., Welch, V.J., McGuire, A.M., 1996. An immunohistochemical method for detecting bradyzoite antigen (BAG5) in *Toxoplasma gondii*-infected tissues cross-reacts with a *Neospora caninum* bradyzoite antigen. *J. Parasitol.* 82, 354–355.
- Pols, J.W., 1960. Studies on bovine besnoitiosis with special reference to the aetiology. *Onderstepoort J. Vet. Res.* 28, 265–356.
- Schulz, K.C.A., Thorburn, J.A., 1955. Globidiosis—a cause of dermatitis in horses. *J. S. Afr. Vet. Assoc.* 26, 39–43.
- Sénaud, J., 1969. Ultrastructure des formations kystiques de *Besnoitia jellisoni* (Frenkel 1953) protozoaire, Toxoplasmea, parasite de la souris (*Mus musculus*). *Protistologica* 5, 413–430.
- Terrell, T.G., Stookey, J.L., 1973. *Besnoitia bennetti* in two Mexican burros. *Vet. Pathol.* 10, 177–184.
- van Heerden, J., Els, H.J., Raubenheimer, E.J., Williams, J.H., 1993. Besnoitiosis in a horse. *J. S. Afr. Vet. Assoc.* 64, 92–95.